UpToDate® Official reprint from UpToDate®
www.uptodate.com © 2023 UpToDate, Inc. and/or its affiliates. All Rights Reserved.

Wolters Kluwer

Clinical manifestations and diagnosis of patent ductus arteriosus in term infants, children, and adults

Authors: Thomas Doyle, MD, Ann Kavanaugh-McHugh, MD
Section Editors: Heidi M Connolly, MD, FACC, FASE, John K Triedman, MD
Deputy Editor: Carrie Armsby, MD, MPH

All topics are updated as new evidence becomes available and our peer review process is complete.

Literature review current through: Feb 2023. | **This topic last updated:** Apr 29, 2022.

INTRODUCTION

The ductus arteriosus (DA) is a fetal vascular connection between the main pulmonary artery and the aorta (figure 1) that diverts blood away from the pulmonary bed. After birth, the DA undergoes active constriction and eventual obliteration. A patent ductus arteriosus (PDA) occurs when the DA fails to completely close postnatally. (See "Physiologic transition from intrauterine to extrauterine life".)

The clinical manifestations and diagnosis of PDA in full-term infants, older children, and adults will be reviewed here. PDA in the premature infant and the management of PDA are discussed separately. (See "Patent ductus arteriosus in preterm infants: Pathophysiology, clinical manifestations, and diagnosis" and "Management of patent ductus arteriosus in term infants, children, and adults".)

DUCTAL EMBRYOLOGY AND ANATOMY

The DA is thought to derive from the embryonic left sixth aortic arch (figure 2 and image 1). In the typical left aortic arch, the aortic end of the DA arises distal to the left subclavian artery and the pulmonary end inserts at the junction of the main and left pulmonary arteries.

The anatomy is more varied in the presence of a right aortic arch. Most commonly, the DA arises from the left innominate artery and inserts into the region of the proximal left pulmonary artery [1]. Less frequently, the DA arises distal to the right subclavian artery and inserts near the proximal right pulmonary artery. In rare instances, there is a bilateral DA, usually in the presence of other complex congenital cardiovascular anomalies.

Regardless of the aortic arch orientation, the vascular structures remain anterior to the trachea and esophagus and there is no vascular ring. One exception to this general rule occurs when there is a right aortic arch with an aberrant left subclavian artery. In this setting, the DA typically arises from the aberrant subclavian artery and inserts into the proximal left pulmonary artery. This creates a vascular ring with the aorta anterior to and rightward of the trachea and esophagus; the aberrant subclavian artery is posterior, and the DA is along the left side, connecting the subclavian to the pulmonary artery. (See "Vascular rings and slings", section on 'Right aortic arch with aberrant left subclavian artery and left-sided ductus arteriosus/ligamentum'.)

Histologically, ductal tissue differs from that of the adjacent aorta and pulmonary artery. The intima of the ductus is thicker, and the media contains more smooth muscle fibers arranged in a characteristic spiral fashion [2]. The DA may take a variety of shapes and forms. The Krichenko classification describes the angiographic appearance of the patent ductus, including several subtypes broadly defined as [3]:

- Type A – Conical with the narrowest portion at the pulmonary artery side
- Type B – Short with narrowing at the aortic insertion
- Type C – Tubular without constriction
- Type D – Tubular with multiple constrictions
- Type E – Bizarre configurations, with an elongated, conical appearance and with the constriction remote from the anterior border of the trachea

An "F type" or "fetal type" ductus has also been described in premature infants presenting for catheter closure [4]. In this subtype, the elongated ductus angles like a hockey stick at the insertion to the pulmonary artery.

This classification scheme does not include the reverse-oriented ductus, which is commonly associated with congenital heart disease.

FETAL AND TRANSITIONAL DUCTAL CIRCULATION

In the fetus, the right ventricle accommodates approximately 60 percent of the total cardiac output [5]. The pulmonary vasculature is constricted, resulting in a high vascular resistance within the pulmonary bed. In contrast, the placenta creates a very low resistance bed arising from the aorta and systemic vascular resistance is low. As a result, the majority of blood exiting from the right ventricle passes right-to-left across the DA into the descending aorta and on to the placenta. (See "Physiologic transition from intrauterine to extrauterine life", section on 'Fetus'.)

In the fetus, the DA is large, with a diameter approximating that of the descending aorta. With the onset of respiration after delivery, the lungs expand and the systemic oxygen saturation rises, resulting in pulmonary vasodilatation and a drop in pulmonary vascular resistance. At the same time, systemic resistance rises with placental removal after cutting the umbilical cord. These factors lead to a sudden reversal of blood flow in the DA from right-to-left to left-to-right. (See "Physiologic transition from intrauterine to extrauterine life", section on 'Transition at delivery'.)

Patency of the ductus — The fetal DA is kept patent by low arterial oxygen content and circulating prostaglandin E2 (PGE2), which is produced in part by the placenta [6]. PGE2 appears to be mediated by its cyclooxygenase (COX)-2 isoform since constriction of the fetal DA in mice is induced by selective COX-2 inhibitors but not selective COX-1 inhibitors [7]. The rationale for the administration of nonsteroidal antiinflammatory drugs in the treatment of PDA in preterm infants is based upon the role of PGE2 in maintaining DA patency. (See "Patent ductus arteriosus in preterm infants: Management", section on 'Indomethacin'.)

Ductal constriction — At birth, the rise in systemic arterial oxygen tension and a decrease in circulating PGE2 levels trigger ductal constriction.

Multiple pathways have been implicated in active ductal constriction including induction of endothelin 1, production of isoprostanes, and inhibition of oxygen-sensitive potassium channels [8,9]. Other potential mediators that may play a role in promoting ductal constriction include angiotensin II, vascular endothelial growth factor, oxygen-sensitive channel, RH1 kinase family members, and cholinergic and adrenergic nerve stimulation [8-11].

After delivery, circulating PGE2 levels fall because of reduced production following removal of the placenta and increased PGE2 clearance due to increase in circulating levels of prostaglandin dehydrogenase [7,12]. Removal of the strong vasodilatory effect of PGE2 is sensed by the PGE2 receptor (EP4) and promotes further constriction of the ductus [13,14].

Constriction of the DA usually results in functional hemodynamic closure within 10 to 15 hours after delivery [15,16]. Closure begins at the pulmonary end of the DA, proceeds toward the

aortic end [17], and is usually completed by two to three weeks of age. Following initial constriction, a series of histologic changes result in obliteration of the ductus and conversion into the ligamentum arteriosum [17]. It appears that these changes do not occur in a PDA, suggesting distinct anatomic differences in the DA tissue [17].

EPIDEMIOLOGY

Incidence — The reported incidence of an isolated PDA among term infants ranges from 3 to 8 per 10,000 live births [18,19]. In a population-based study of 400,000 term infants born in Atlanta from 1998 to 2005, the reported incidence of PDA was 2.9 per 10,000 live births [19]. In this study, the diagnosis was defined as a PDA persisting up to or beyond six weeks after delivery in infants with a gestational age at or greater than 36 weeks and excluded patients with obligatory shunt lesions due to complex congenital heart disease or those who received prostaglandin therapy.

There is a female predominance for PDA, with a 2:1 female-to-male ratio in most case series of term infants [19,20]. The incidence of PDA is also greater in infants born at high altitude compared with those born at sea level [12], and in infants with congenital rubella. (See "Congenital rubella", section on 'Clinical features'.)

One of the most important risk factors for PDA is prematurity. The effect of prematurity on the incidence of PDA is discussed separately. (See "Patent ductus arteriosus in preterm infants: Pathophysiology, clinical manifestations, and diagnosis".)

PDA may present with other congenital heart lesions, especially those associated with hypoxemia. PDA should be considered when the clinical features of left-to-right shunt seem out of proportion to the particular lesion being considered.

Genetic factors — It is likely that genetic factors contribute to some cases of PDA. Siblings of patients with PDA have an increased frequency of this abnormality (2 to 4 percent) [21]. PDA occasionally occurs in many members of multiple generations of a family, making simple autosomal dominant inheritance likely in these families [22]. A notable example of this is Char syndrome, which is caused by heterozygous mutation in the *TFAP2B* gene [23]. Affected individuals have PDA, unusual facial features (including a broad, high forehead; flat profile; and short nose with a broad, flattened tip), and abnormalities of the fifth digit of the hand (including clinodactyly and distal interphalangeal joint symphalangism). *TFA2B* mutations have also been found in individuals with nonsyndromic PDA [24,25]. Variants in other genes have also been associated with PDA, including *MYH11*, *ACTA2*, *TRAF1*, and *AGTR1* [26].

PDA can occur in several genetic syndromes, including [26,27]:

- Cantú syndrome
- CHARGE syndrome
- Cri-du-chat syndrome (see "Congenital cytogenetic abnormalities", section on '5p deletion syndrome (cri-du-chat syndrome)')
- DiGeorge syndrome (see "DiGeorge (22q11.2 deletion) syndrome: Clinical features and diagnosis")
- Down syndrome (see "Down syndrome: Clinical features and diagnosis")
- Holt-Oram syndrome
- Loeys-Dietz syndrome (see "Genetics, clinical features, and diagnosis of Marfan syndrome and related disorders", section on 'TGFBR1 or TGFBR2 mutation: Loeys-Dietz syndrome')
- Mowat-Wilson syndrome (see "Congenital aganglionic megacolon (Hirschsprung disease)", section on 'Associated syndromes')
- Noonan syndrome (see "Noonan syndrome")
- Periventricular nodular heterotopia
- Rubinstein-Taybi syndrome (see "Microdeletion syndromes (chromosomes 12 to 22)", section on '16p13.3 deletion syndrome (Rubinstein-Taybi syndrome)')

CLINICAL MANIFESTATIONS

The clinical manifestations of a PDA are determined by the degree of left-to-right shunting, which is dependent upon the size and length of the PDA, and the difference between pulmonary and systemic vascular resistances.

The hemodynamic consequences of the PDAs can be categorized by the degree of left-to-right shunting based upon the pulmonary-to-systemic-flow ratio (Qp:Qs) [28].

- Small – Qp:Qs <1.5 to 1
- Moderate − Qp:Qs between 1.5 and 2.2 to 1
- Large − Qp:Qs >2.2 to 1

The clinical findings for the full-term infant, older children, and adults based upon the size of PDA are discussed in the next sections. The clinical manifestations of PDA in preterm infants are discussed separately. (See "Patent ductus arteriosus in preterm infants: Pathophysiology, clinical manifestations, and diagnosis".)

Small patent ductus arteriosus — A small PDA (Qp:Qs <1.5 to 1) that restricts excessive blood flow into the lungs may go undetected, and the patient will have no identifiable symptoms. These patients are commonly identified incidentally by the detection of the characteristic continuous flow murmur (movie 1) noted during a routine primary care visit or by a finding of a PDA on a diagnostic study (eg, computed tomography or echocardiography) performed for other medical conditions [29].

In patients with a small PDA, the physical examination reveals normal precordial activity and normal first and second heart sounds (S1 and S2). Pulses are normal or only mildly accentuated. The respiratory examination also is unremarkable, and there is no evidence of cyanosis.

A murmur is commonly present, and its characteristics vary between the neonate and older patients because of changes in the relative differences between pulmonary and systemic vascular resistances:

- Neonates – In the newborn, aortic systolic pressure is greater than pulmonary systolic pressure, but this gradient may not be present during diastole. As a result, the murmur may be confined to systole.

- After the newborn period – Pulmonary artery pressure falls after the newborn period. As a result, aortic pressure is higher than pulmonary artery pressure during both systole and diastole, producing continuous flow through the ductus and a characteristic continuous murmur (movie 1) (Gibson's murmur or machinery murmur). The murmur is grade 3/6 or less and is heard best in the left infraclavicular region. The intensity of the murmur is maximal immediately before and after the S2 and is not affected by position. (See "Common causes of cardiac murmurs in infants and children", section on 'Patent ductus arteriosus' and "Auscultation of cardiac murmurs in adults", section on 'Patent ductus arteriosus'.)

Infective endarteritis is an uncommon presentation and complication of small PDAs. It appears to occur more frequently in patients in resource-limited countries. In one case series of 14 Pakistani patients, fever was the presenting symptom and the presence of a heart murmur was detected upon physical examination in all patients [30]. The diagnosis of PDA was confirmed by echocardiography, and vegetations were detected in 12 of the 14 patients. (See 'Infective endocarditis' below.)

Moderate patent ductus arteriosus — Patients with moderate-size PDAs (Qp:Qs between 1.5 and 2.2 to 1) may present with exercise intolerance. In these patients, the moderate left-to-right shunt increases the volume load on the left atrium and ventricle, which results in left ventricular dilation and dysfunction.

The characteristic continuous murmur (usually grade 2 or 3 and occasionally grade 4) in the left infraclavicular area, which is louder than that associated with a small PDA, is typically accompanied by a wide systemic pulse pressure and signs of left ventricular volume overload, such as a displaced left ventricular apex.

Large patent ductus arteriosus — A large PDA (Qp:Qs >2.2 to 1) initially causes left ventricular volume overload. Over time, there may be a progressive rise in pulmonary artery pressures, which, in the uncorrected patient, may lead to irreversible pulmonary vascular changes. With sufficiently increased pulmonary vascular resistance, flow reverses to a right-to-left shunt, and over time, these patients develop cyanotic heart disease (ie, Eisenmenger syndrome). The characteristic continuous murmur decreases as the pulmonary pressure rises and ultimately disappears. The pulmonary component of S2 increases (movie 2). (See "Pulmonary hypertension with congenital heart disease: Clinical manifestations and diagnosis".)

In the infant, a large PDA may present with signs of heart failure, including failure to thrive, poor feeding, and respiratory distress. The older child may present with shortness of breath or easy fatigability.

In the uncorrected adult, a large PDA may present with a short systolic ejection murmur and features of Eisenmenger syndrome including cyanosis and clubbing. Patients with PDA and Eisenmenger syndrome typically have cyanosis and clubbing that is more pronounced in the lower extremities (ie, differential cyanosis) because the ductus typically delivers unoxygenated blood distal to the left subclavian artery.

In the patient with a large left-to-right shunt, precordial palpation reveals a dynamic left ventricular impulse and a thrill, and the pulses are bounding with a wide pulse pressure due to runoff into the pulmonary bed. On auscultation, S1 is normal, S2 may be split with an accentuated pulmonary component, and eddy sounds may be heard in late systole and early diastole. A grade 4/6 continuous murmur is heard in the left infraclavicular region. An apical diastolic rumble induced by increased flow across the mitral valve may be present, preceded by a third heart sound.

As mentioned above, adult patients with PDA may have a short systolic ejection murmur because the diastolic runoff into the pulmonary circulation is decreased due to increasing pulmonary vascular resistance. With increasing pulmonary vascular resistance, patients may develop pulmonary hypertension. (See 'Pulmonary hypertension' below.)

DIAGNOSIS

The diagnosis of PDA is usually based upon its characteristic clinical findings and typically confirmed by echocardiography. The chest radiograph and the electrocardiogram may be helpful but are less sensitive and specific than echocardiography. Cardiac catheterization and angiography are generally only necessary when percutaneous therapy is being considered or in the context of more complex congenital heart disease.

Echocardiography — A complete echocardiographic evaluation of a PDA includes anatomic confirmation by two-dimensional imaging and Doppler echocardiography hemodynamic assessment, including the degree of shunting and pulmonary artery pressure [31,32].

Two-dimensional echocardiography — The PDA can be imaged in many views using two-dimensional echocardiographic imaging and superimposed Doppler color flow mapping [31,32]. Most commonly, the ductus is imaged in the parasternal and suprasternal notch views.

- Parasternal views − In the high parasternal short-axis view, with the transducer oriented leftward toward the pulmonary artery bifurcation, the ductus can be imaged connecting the pulmonary artery and the descending aorta (movie 3 and movie 4). In this view, the ductus can be seen arising from the anterior aspect of the descending aorta, which is viewed in cross section. The patent ductus enters the pulmonary artery near the origin of the left pulmonary artery.

- Suprasternal views − In the suprasternal notch window, the ductus arises from the descending aorta at the level of the left subclavian artery and courses anteriorly to join the pulmonary artery (movie 5 and movie 6). Moving the transducer just laterally and inferiorly to an infraclavicular position, and rotating clockwise, permits further imaging of the ductus and its relationship to the branch pulmonary arteries and descending aorta (movie 7).

In patients with a right aortic arch, the ductus usually arises from the left brachiocephalic vessels instead of the descending aorta and can be followed caudally to its insertion on the pulmonary artery in the suprasternal view.

The presence of a PDA may mask an aortic coarctation since the ductus augments the left aortic arch at its origin. The presence of a bicuspid aortic valve, hypoplasia of the transverse arch or aortic isthmus, a long distance between the left carotid and subclavian origins, or a posterior shelf should alert the echocardiographer to the possible presence of a coexistent coarctation (see "Clinical manifestations and diagnosis of aortic stenosis in adults"). An aortic coarctation probability model has been validated for use in neonates with a PDA [33]. Using this model, echocardiographic measurements of the aortic arch may be used to risk stratify infants

according to likelihood of the evolution of coarctation with ductal closure, which is used to guide patient management.

Two-dimensional imaging may give important qualitative information regarding the hemodynamic significance of a PDA. Left atrial and ventricular dilation are seen in the presence of a large left-to-right shunt.

Doppler color flow — Doppler color flow mapping can supplement imaging of the PDA, which is most commonly seen as a retrograde color flow jet in the pulmonary artery. This jet usually occurs along the leftward aspect of the pulmonary artery but may be directed into the center or more rightward. In patients with normal pulmonary artery pressure, the high-velocity turbulent flow is easily seen in both systole and diastole (movie 3). In patients with high pulmonary vascular resistance, the retrograde jet may be visible only in diastole (movie 4).

Color flow mapping is particularly helpful in the setting of a small PDA that may be difficult to identify by two-dimensional imaging, especially in adults in whom resolution is more limited than in infants and small children. Determination of the origin of the retrograde flow into the pulmonary artery using two-dimensional imaging as well as color flow mapping is crucial to avoid confusion of the patent ductus with other aortopulmonary shunts, such as collateral vessels, coronary artery fistulae, or an aortopulmonary window. (See 'Differential diagnosis' below.)

Doppler echocardiography — Doppler echocardiography can estimate the degree of left-to-right shunt and assess the pulmonary artery pressure. When the pulmonary artery pressure is lower than systemic arterial pressure, there is continuous left-to-right shunting, demonstrated by both color flow mapping and pulsed Doppler interrogation. The peak velocity of flow across the ductus, measured by either pulsed or continuous-wave Doppler, can be translated into the gradient between the aorta and the pulmonary artery using the modified Bernoulli equation. This Doppler-derived gradient correlates with gradients measured at catheterization and can be subtracted from the cuff pressure to estimate pulmonary artery pressure (image 2). Low peak velocity and corresponding low gradient suggest high pulmonary artery pressure. Low peak velocity that further decreases rapidly in diastole suggests a hemodynamically significant PDA.

As with any Doppler-derived measurement, care must be taken to minimize the angle between the Doppler interrogation and the direction of flow in the ductus. The length and shape of the ductus may influence the accuracy of gradient estimates using the Bernoulli equation; longer and more "tunnel"-like structures are less reliably evaluated using this equation [32].

In the setting of a large left-to-right shunt at the DA, continuous runoff can be seen in the branch pulmonary arteries and in the aorta proximal to the PDA by pulsed Doppler echocardiography (image 3). Distal to the origin of the PDA, diastolic retrograde flow can be demonstrated, corresponding to the runoff into the pulmonary artery (image 4) [34].

When the pulmonary artery pressure is equal to systemic pressure, pulsed Doppler echocardiography within the ductus demonstrates systolic right-to-left shunting, with diastolic left-to-right flow within the vessel (movie 4 and image 5). The finding of systolic right-to-left flow within the ductus may be confused with normal antegrade systolic flow in the left pulmonary artery if the sample volume is not placed within the ductus. In rare cases of arch abnormalities and pulmonary hypertension, right-to-left shunting may be seen throughout the cardiac cycle [35,36].

The pulmonary-to-systemic-flow ratio (Qp:Qs) can be estimated echocardiographically using the area of the left and right ventricular outflow tracts and Doppler-derived velocity and flow data. Paradoxically, in the setting of the PDA, the systemic blood flow is calculated by using the area of the right ventricular and pulmonary outflow tracts and velocity time integrals, and the pulmonary blood flow is calculated utilizing the aortic outflow tract area and velocity time integral. However, the ductal jet frequently distorts the antegrade pulmonary flow signal; as a result, this measurement is not usually helpful [31].

Information regarding right ventricular and pulmonary artery pressure may also be derived by determination of tricuspid regurgitation velocity and, qualitatively, by ventricular septal configuration.

Transesophageal echocardiography can be used for identification of a PDA, but the PDA may be difficult to visualize using this technique.

M-mode echocardiography — Although M-mode echocardiography may reveal findings suggesting a left-to-right shunt, it is not diagnostic for a PDA. A ratio of left atrial-to-aortic diameter greater than 1.5:1 is usually associated with significant left-to-right shunting.

Other diagnostic tests

Chest radiograph — The findings on chest radiography vary with the size of the ductus and the degree of left-to-right shunting. In patients with a small PDA (ie, restrictive), the chest radiograph is normal.

The earliest radiographic finding usually is a prominent main pulmonary artery segment blending with a prominent aortic knob along the upper left heart border. In patients with

moderate-size PDAs, the heart is slightly enlarged and the pulmonary vascular markings are increased. In patients with a large PDA, these features become more pronounced, with enlargement of the left ventricle and atrium and increased pulmonary vascular markings.

Electrocardiogram — The electrocardiogram is often normal in patients with a small PDA. In contrast, a large PDA with a large left-to-right shunt typically produces electrocardiographic findings of biventricular hypertrophy and a left atrial abnormality. With longstanding pulmonary hypertension, the ductus shunt is reversed and signs of right ventricular hypertrophy predominate. (See "ECG tutorial: Chamber enlargement and hypertrophy".)

Magnetic resonance imaging and computed tomography — Magnetic resonance imaging and computed tomography are other imaging modalities. However, they are not generally used, because echocardiography typically provides adequate imaging and additional functional information that is not provided by computed tomography and magnetic resonance imaging and is less costly.

DIFFERENTIAL DIAGNOSIS

PDA can usually be distinguished from other lesions associated with continuous murmurs, bounding pulses, and heart failure by the physical examination and can be completely differentiated by echocardiography [37].

- **Continuous murmurs** – The PDA murmur (movie 1) is distinguished from other causes of continuous murmurs based on the location and quality of the murmur (see "Approach to the infant or child with a cardiac murmur"):
  - A venous hum (movie 8) is more often located on the right side and changes with position and local compression
  - Murmurs of systemic arteriovenous malformations or fistulas are heard in extracardiac locations
  - Murmurs of coronary artery fistulas (movie 9) are most often located over the lower precordium
  - The aortopulmonary window often has only a systolic murmur
  - Combined aortic stenosis and aortic regurgitation (movie 10), combined pulmonic stenosis and pulmonic regurgitation (movie 11), and ventricular septal defect

associated with semilunar valve regurgitation are characterized by systolic and diastolic murmurs (ie, to-and-fro murmurs), rather than continuous murmurs

- The murmur of a ruptured sinus of Valsalva aneurysm is typically a new continuous murmur loudest at the second left interspace

- **Bounding pulses** – Bounding pulses may be seen with other aortic runoff lesions and in systemic infection (ie, warm septic shock):
  - Aortic regurgitation produces a diastolic murmur (movie 12A-B) (see "Aortic regurgitation in children" and "Clinical manifestations and diagnosis of chronic aortic regurgitation in adults")
  - Truncus arteriosus is associated with cyanosis (see "Truncus arteriosus")
  - Aortopulmonary window (see "Auscultation of cardiac murmurs in adults", section on 'Aortopulmonary window')
  - Sepsis is associated with other signs of systemic infection (eg, fever, abnormal white blood cell count) (see "Systemic inflammatory response syndrome (SIRS) and sepsis in children: Definitions, epidemiology, clinical manifestations, and diagnosis", section on 'Shock')
- **Heart failure** – Symptoms of heart failure (eg, poor feeding in infants, shortness of breath, or easy fatigability in older children) may be seen with other lesions that cause pulmonary overcirculation in the setting of a large amount of left-to-right shunting. Large ventricular septal defects are a common cause of heart failure in infants. The murmur associated with a ventricular septal defect is typically holosystolic (movie 13). Other lesions that cause volume overload are discussed separately. (See "Heart failure in children: Etiology, clinical manifestations, and diagnosis", section on 'Volume overload with preserved ventricular contractility'.)

COMPLICATIONS

Individuals with PDA have increased morbidity and mortality, primarily due to heart failure and, rarely, infective endocarditis (IE) [38]. Pulmonary vascular disease is an uncommon problem.

Heart failure — If untreated, a large PDA can cause significant cardiac volume overload, resulting in heart failure. This most commonly occurs in the young infant and in older patients,

whose left atrial and ventricular function have been impaired due to the effects of chronic volume workload. In older patients, heart failure is often associated with atrial fibrillation.

Infants with heart failure will present with failure to thrive, poor feeding, and respiratory distress. Initial management includes digoxin and diuretic therapy until they are candidates for device or surgical closure. (See "Management of patent ductus arteriosus in term infants, children, and adults".)

Infective endocarditis — IE is a rare complication of PDA [39-41]. When IE does occur, the vegetations usually accumulate at the pulmonary end of the PDA and shower the lungs with septic emboli.

Estimates of the magnitude of risk of IE in patients with PDA vary. In one report, PDA was the underlying lesion in 15 percent of pediatric IE cases [30]. In a population-based registry that included 620 patients who underwent surgical PDA ligation in childhood, there were no cases of IE over a total of 8751 patient-years of follow-up [40]. In another study that reviewed the records of 270 pediatric and adult patients with PDA, no cases of IE were observed over an aggregate of 1196 patient-years [39]. In a study of adult patients with congenital heart disease, the incidence of IE among those with PDA was 0.24 per 1000 patient-years [42]. Some experts have argued that the risk of endocarditis is so low that closure of a small PDA for the sole purpose of preventing IE may not be warranted [39,43]. (See "Native valve endocarditis: Epidemiology, risk factors, and microbiology", section on 'Congenital heart disease'.)

Patients with isolated PDA do **not** require antibiotic prophylaxis for IE. Indications for prophylaxis are discussed separately. (See "Management of patent ductus arteriosus in term infants, children, and adults", section on 'Antibiotic prophylaxis' and "Prevention of endocarditis: Antibiotic prophylaxis and other measures".)

Pulmonary hypertension — An isolated large PDA, as with any large left-to-right shunt, is a risk factor for irreversible pulmonary vascular disease. (See "The epidemiology and pathogenesis of pulmonary arterial hypertension (Group 1)".)

In patients who develop pulmonary artery hypertension (PAH), the continuous PDA murmur is absent and auscultation reveals a pulmonary ejection sound, a loud single second heart sound (S2) (movie 2), and, in some cases, a Graham Steell murmur. The Graham Steell murmur of pulmonic regurgitation and PAH is high pitched and "blowing." It begins with an accentuated P2 of S2 and can be of variable duration. In addition, precordial palpation often reveals a right ventricular impulse. (See "Auscultation of cardiac murmurs in adults", section on 'Pulmonic regurgitation'.)

PAH may lead to right-to-left shunting, with resulting cyanosis and clubbing in the lower extremities (ie, Eisenmenger syndrome). (See "Pulmonary hypertension with congenital heart disease: Clinical manifestations and diagnosis".)

PDA appears to be a relatively common cause of PAH of unknown etiology in adolescents and adults. In one series of 24 patients with unexplained PAH, 16 were found to have left-to-right shunting defects on transesophageal echocardiography (atrial septal defect in eight, PDA in six, and ventricular septal defect in two) [44].

Complications during pregnancy — Pregnancy in women with congenital heart disease (unrepaired or repaired) poses potential risks to the mother and fetus. The general principles of this problem are discussed separately. (See "Pregnancy in women with congenital heart disease: General principles".)

Unrepaired PDA is a cause of left-to-right shunt that may be encountered among expectant mothers, although operative or interventional catheter closure is routine and curative in childhood. Most commonly, an asymptomatic young woman with a restrictive (ie, small) PDA can anticipate an uncomplicated pregnancy. Less frequently, a moderate or large PDA with significant shunting can cause elevated pulmonary vascular resistance, complicating the pregnancy.

In the case of left-to-right ductal shunting, the gestational fall in systemic vascular resistance may serve to decrease ductal flow, but this benefit is unlikely to compensate for the hemodynamic burden of pregnancy. Patients with a nonrestrictive PDA, pulmonary vascular disease, and a reversed shunt (ie, Eisenmenger syndrome) are at high risk for significant morbidity and mortality and are advised against pregnancy. (See "Pulmonary hypertension with congenital heart disease: Pregnancy and contraception".)

Division of a restrictive or moderately restrictive PDA in childhood is considered curative. However, closure of a nonrestrictive ductus may be followed by an incomplete decline in pulmonary vascular resistance or by incomplete functional recovery of the volume-overloaded left ventricle or the pressure-overloaded right ventricle. Postoperative pulmonary vascular disease and depressed ventricular function are important residua that can increase gestational risk.

SUMMARY AND RECOMMENDATIONS

- **Anatomy and incidence** – The ductus arteriosus (DA) is a fetal vascular connection between the main pulmonary artery and the aorta that normally closes soon after birth

(figure 1). Patent ductus arteriosus (PDA) results from failure of the DA to completely close postnatally. Among term infants, PDA occurs in 3 to 8 per 10,000 live births. (See 'Ductal embryology and anatomy' above and 'Fetal and transitional ductal circulation' above and 'Epidemiology' above.)

- **Clinical manifestations** – The clinical manifestations of a PDA vary depending on the size and length of the PDA and the degree of left-to-right shunting (see 'Clinical manifestations' above):
  - Patients with small PDAs generally are asymptomatic and are detected on the basis of a murmur (movie 1) heard incidentally during routine physical examination or testing for other conditions. (See 'Small patent ductus arteriosus' above.)
  - In patients with moderate and large PDAs, symptoms can range from exertional dyspnea to heart failure. (See 'Moderate patent ductus arteriosus' above and 'Large patent ductus arteriosus' above.)
  - Adults with uncorrected large PDAs may develop pulmonary vascular disease, resulting in right-to-left shunting and cyanosis (ie, Eisenmenger syndrome). (See "Pulmonary hypertension with congenital heart disease: Clinical manifestations and diagnosis".)
- **Diagnosis** – The diagnosis of PDA is usually suspected based upon the presence of a characteristic continuous flow murmur (movie 1). The diagnosis is confirmed with echocardiography. (See 'Diagnosis' above.)
- **Differential diagnosis** – The differential diagnosis of PDA includes other causes of diastolic murmurs, bounding pulses, and heart failure. (See 'Differential diagnosis' above.)
- **Complications** – Complications of PDA include heart failure, infective endocarditis (IE), pulmonary hypertension, and risks during pregnancy. (See 'Complications' above.)

ACKNOWLEDGMENT

The UpToDate editorial staff acknowledges Thomas Graham Jr, MD, who contributed to an earlier version of this topic review.

Use of UpToDate is subject to the Terms of Use.

REFERENCES

1. Knight L, Edwards JE. Right aortic arch. Types and associated cardiac anomalies. Circulation 1974; 50:1047.
2. Moss and Adams' Heart Disease in Infants, Children and Adolescents: Including the Fetus a nd Young Adult, 7th ed, Allen HD, Driscoll DJ, Shaddy RE, Feltes T (Eds), Lippincott Williams and Wilkins, 2007.
3. Krichenko A, Benson LN, Burrows P, et al. Angiographic classification of the isolated, persistently patent ductus arteriosus and implications for percutaneous catheter occlusion. Am J Cardiol 1989; 63:877.
4. Sathanandam S, Balduf K, Chilakala S, et al. Role of Transcatheter patent ductus arteriosus closure in extremely low birth weight infants. Catheter Cardiovasc Interv 2019; 93:89.
5. Rudolph AM. The changes in the circulation after birth. Their importance in congenital heart disease. Circulation 1970; 41:343.
6. Smith GC. The pharmacology of the ductus arteriosus. Pharmacol Rev 1998; 50:35.
7. Loftin CD, Trivedi DB, Langenbach R. Cyclooxygenase-1-selective inhibition prolongs gestation in mice without adverse effects on the ductus arteriosus. J Clin Invest 2002; 110:549.
8. Thébaud B, Michelakis ED, Wu XC, et al. Oxygen-sensitive Kv channel gene transfer confers oxygen responsiveness to preterm rabbit and remodeled human ductus arteriosus: implications for infants with patent ductus arteriosus. Circulation 2004; 110:1372.
9. Clyman RI. Mechanisms regulating the ductus arteriosus. Biol Neonate 2006; 89:330.
10. Waleh N, Seidner S, McCurnin D, et al. Anatomic closure of the premature patent ductus arteriosus: The role of CD14+/CD163+ mononuclear cells and VEGF in neointimal mound formation. Pediatr Res 2011; 70:332.
11. Crockett SL, Berger CD, Shelton EL, Reese J. Molecular and mechanical factors contributing to ductus arteriosus patency and closure. Congenit Heart Dis 2019; 14:15.
12. Coggins KG, Latour A, Nguyen MS, et al. Metabolism of PGE2 by prostaglandin dehydrogenase is essential for remodeling the ductus arteriosus. Nat Med 2002; 8:91.
13. Nguyen M, Camenisch T, Snouwaert JN, et al. The prostaglandin receptor EP4 triggers remodelling of the cardiovascular system at birth. Nature 1997; 390:78.
14. Segi E, Sugimoto Y, Yamasaki A, et al. Patent ductus arteriosus and neonatal death in prostaglandin receptor EP4-deficient mice. Biochem Biophys Res Commun 1998; 246:7.
15. Heymann MA, Rudolph AM. Control of the ductus arteriosus. Physiol Rev 1975; 55:62.
16. Iwashima S, Satake E, Uchiyama H, et al. Closure time of ductus arteriosus after birth based

on survival analysis. Early Hum Dev 2018; 121:37.

17. Gittenberger-de Groot AC, Strengers JL, Mentink M, et al. Histologic studies on normal and persistent ductus arteriosus in the dog. J Am Coll Cardiol 1985; 6:394.
18. Hoffman JI, Kaplan S. The incidence of congenital heart disease. J Am Coll Cardiol 2002; 39:1890.
19. Reller MD, Strickland MJ, Riehle-Colarusso T, et al. Prevalence of congenital heart defects in metropolitan Atlanta, 1998-2005. J Pediatr 2008; 153:807.
20. RECORD RG, McKEOWN T. Observations relating to the aetiology of patent ductus arteriosus. Br Heart J 1953; 15:376.
21. Nora JJ. Multifactorial inheritance hypothesis for the etiology of congenital heart diseases. The genetic-environmental interaction. Circulation 1968; 38:604.
22. Davidson HR. A large family with patent ductus arteriosus and unusual face. J Med Genet 1993; 30:503.
23. Satoda M, Pierpont ME, Diaz GA, et al. Char syndrome, an inherited disorder with patent ductus arteriosus, maps to chromosome 6p12-p21. Circulation 1999; 99:3036.
24. Khetyar M, Syrris P, Tinworth L, et al. Novel TFAP2B mutation in nonsyndromic patent ductus arteriosus. Genet Test 2008; 12:457.
25. Chen YW, Zhao W, Zhang ZF, et al. Familial nonsyndromic patent ductus arteriosus caused by mutations in TFAP2B. Pediatr Cardiol 2011; 32:958.
26. Lewis TR, Shelton EL, Van Driest SL, et al. Genetics of the patent ductus arteriosus (PDA) and pharmacogenetics of PDA treatment. Semin Fetal Neonatal Med 2018; 23:232.
27. Bökenkamp R, DeRuiter MC, van Munsteren C, Gittenberger-de Groot AC. Insights into the pathogenesis and genetic background of patency of the ductus arteriosus. Neonatology 2010; 98:6.
28. Webb GD, Smallhorn FJ, Terrien J, Redington AN. Congenital heart disease. In: Braunwalds' Heart Disease, 8th ed, Libby P, Bonow RO, Mann DL, Zipes DP (Eds), Philadelphia 2008. p.1561.
29. Goitein O, Fuhrman CR, Lacomis JM. Incidental finding on MDCT of patent ductus arteriosus: use of CT and MRI to assess clinical importance. AJR Am J Roentgenol 2005; 184:1924.
30. Sadiq M, Latif F, Ur-Rehman A. Analysis of infective endarteritis in patent ductus arteriosus. Am J Cardiol 2004; 93:513.
31. Silverman NH. Pediatric Echocardiography, Williams & Wilkins, Baltimore 1993. p.173.

32. Snider AR, Serwer GA, Ritter SB. Echocardiography in Pediatric Heart Disease, Mosby-Year Book, St. Louis 1977. p.455.
33. Soslow JH, Kavanaugh-McHugh A, Wang L, et al. A clinical prediction model to estimate the risk for coarctation of the aorta in the presence of a patent ductus arteriosus. J Am Soc Echocardiogr 2013; 26:1379.
34. Serwer GA, Armstrong BE, Anderson PA. Nonivasive detection of retrograde descending aortic flow in infants using continuous wave doppler ultrasonography. Implications for diagnosis of aortic run-off lesions. J Pediatr 1980; 97:394.
35. Cloez JL, Isaaz K, Pernot C. Pulsed Doppler flow characteristics of ductus arteriosus in infants with associated congenital anomalies of the heart or great arteries. Am J Cardiol 1986; 57:845.
36. Hiraishi S, Horiguchi Y, Misawa H, et al. Noninvasive Doppler echocardiographic evaluation of shunt flow dynamics of the ductus arteriosus. Circulation 1987; 75:1146.
37. Mullins CE. Patent ductus arteriosus. In: The Science and Practice of Pediatric Cardiology, Garson A, Bricker JT, McNamara DG (Eds), Lea & Febiger, Philadelphia 1990. p.1055.
38. Campbell M. Natural history of persistent ductus arteriosus. Br Heart J 1968; 30:4.
39. Thilén U, Aström-Olsson K. Does the risk of infective endarteritis justify routine patent ductus arteriosus closure? Eur Heart J 1997; 18:503.
40. Morris CD, Reller MD, Menashe VD. Thirty-year incidence of infective endocarditis after surgery for congenital heart defect. JAMA 1998; 279:599.
41. Lankipalli RS, Lax K, Keane MG, et al. Images in cardiovascular medicine. Infected patent ductus arteriosus. Circulation 2005; 112:e364.
42. Mylotte D, Rushani D, Therrien J, et al. Incidence, Predictors, and Mortality of Infective Endocarditis in Adults With Congenital Heart Disease Without Prosthetic Valves. Am J Cardiol 2017; 120:2278.
43. Fortescue EB, Lock JE, Galvin T, McElhinney DB. To close or not to close: the very small patent ductus arteriosus. Congenit Heart Dis 2010; 5:354.
44. Chen WJ, Chen JJ, Lin SC, et al. Detection of cardiovascular shunts by transesophageal echocardiography in patients with pulmonary hypertension of unexplained cause. Chest 1995; 107:8.

Topic 1421 Version 27.0

GRAPHICS

Patent ductus arteriosus

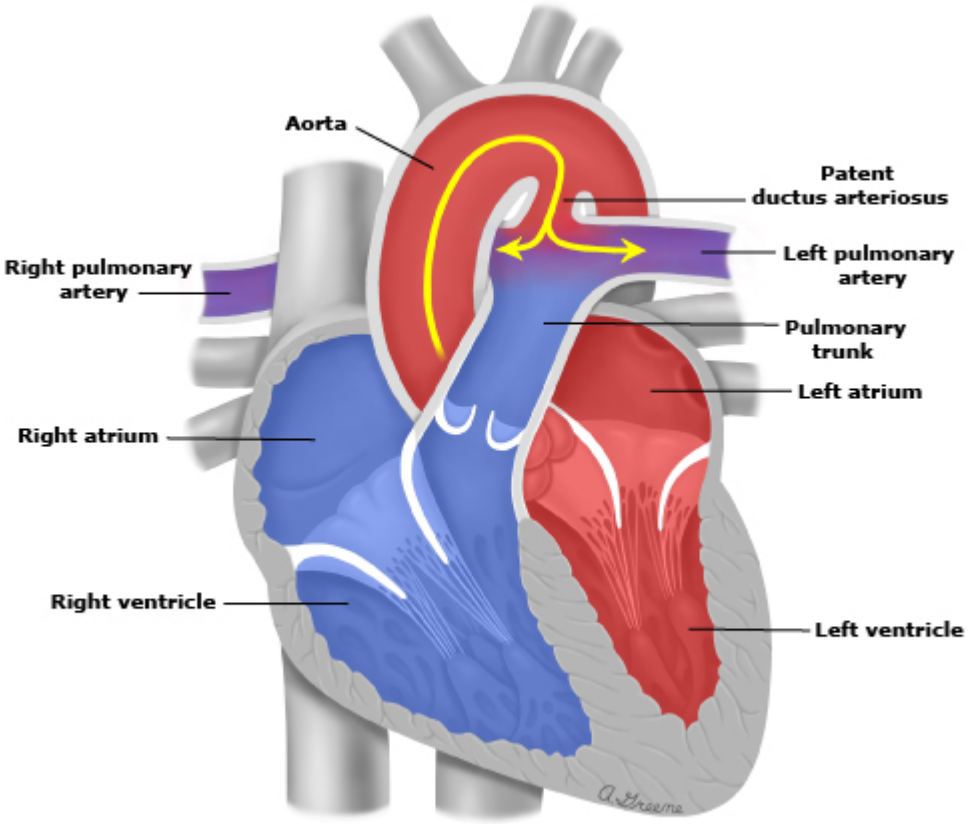

Graphic 65828 Version 2.0

Origin of great vessels and ductus arteriosus

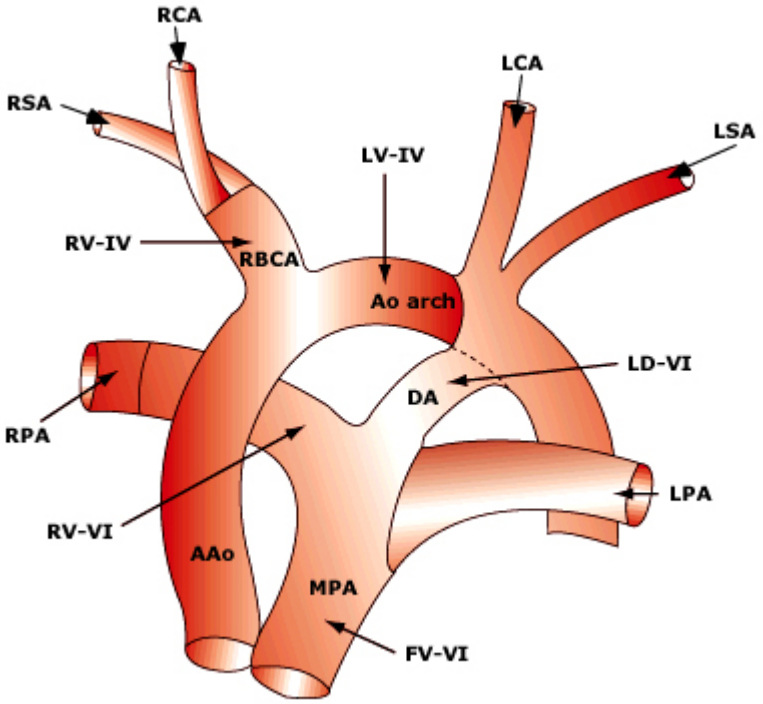

Shown is the morphologic derivation of proximal pulmonary and aortic vessels at birth. The main pulmonary artery (MPA) comes from the fused ventral VIth arterial arch (FV-VI), while the right and left pulmonary arteries (RPA and LPA) come from the right (RV-VI) and left ventral VIth arterial arches (LV-VI). The ascending aorta (AAo) and right brachiocephalic artery (RBCA) are derived from the right ventral IVth arterial arch (RV-IV), while the aortic arch (Ao arch) comes from the left ventral IVth arterial arch (LV-IV). The ductus arteriosus (DA) is derived from the left dorsal VIth arch (LD-VI).

LSA: left subclavian artery; LCA: left carotid artery; RSA: right subclavian artery; RCA: right carotid artery.

With permission from Skidmore FD, Ann R Coll Surg Engl 1975; 57:186.

Graphic 55186 Version 3.0

Patent ductus arteriosus arteriogram

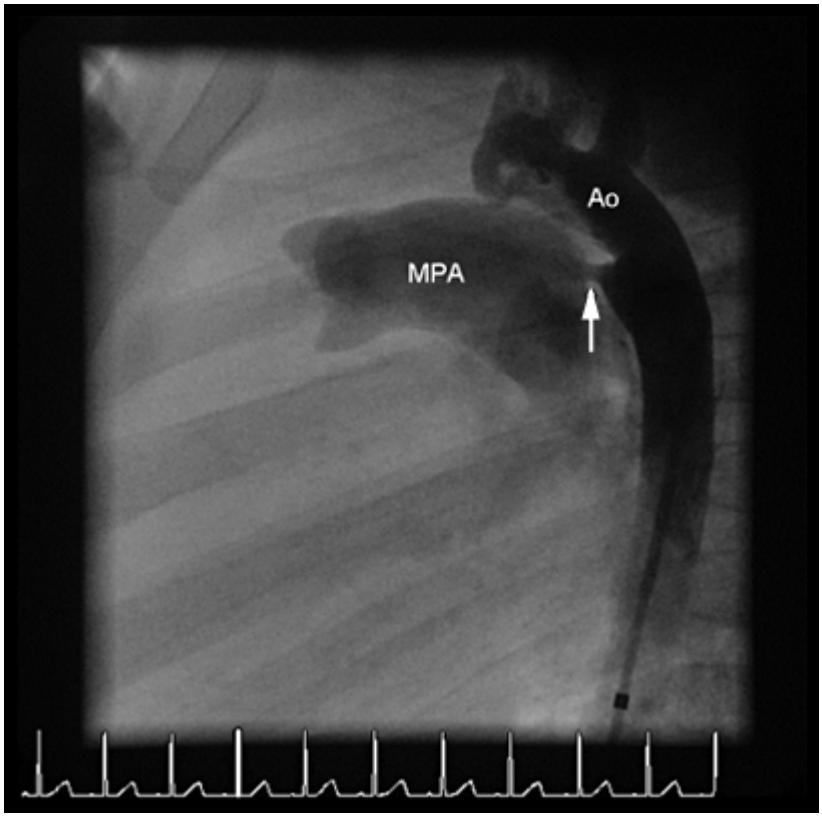

A lateral angiogram of the transverse aortic arch and descending aorta (Ao) demonstrating a patent ductus arteriosus (arrow) with left to right shunt of contrast into the main pulmonary artery (MPA).

Courtesy of Kevin Hill, MD.

Graphic 61946 Version 3.0

Estimation of pulmonary artery pressure using continuous wave Doppler echocardiogram interrogation in a patient with a patent ductus arteriosus

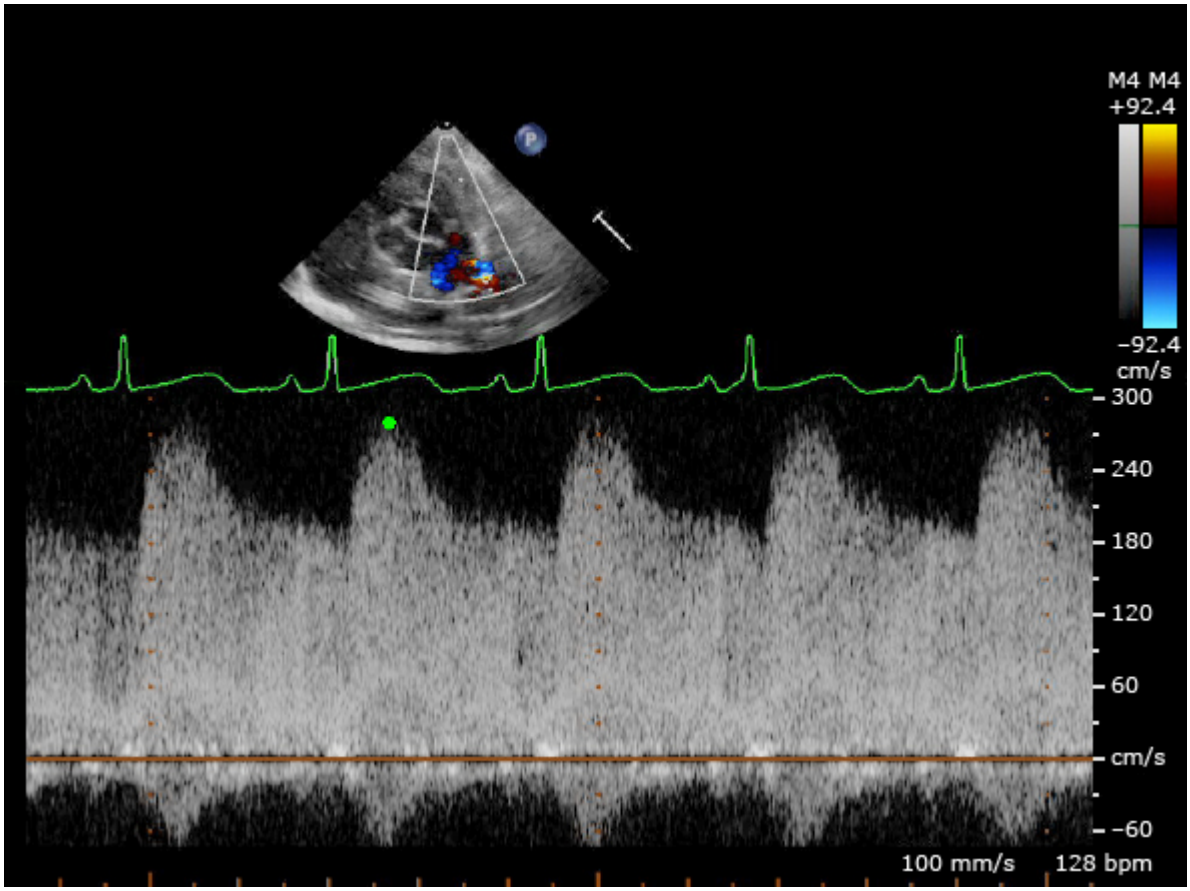

Doppler echocardiogram interrogation is directed into the jet of continuous left-to-right flow in the short axis view of a patient with a patent ductus arteriosus (PDA). The maximum velocity (V) of 2.8 m/sec through the ductus arteriosus is noted by continuous wave Doppler. The peak gradient between the aorta and pulmonary artery is 4 x V^2 or 32 mmHg. The estimated pulmonary artery pressure of 36 mmHg is the difference between the measured systolic blood pressure of 68 mmHg and the peak gradient of 32 mmHg between the aorta and pulmonary artery.

PA: pulmonary artery.

Graphic 95137 Version 1.0

Pulsed wave Doppler interrogation in a patient with patent ductus arteriosus and significant left-to-right shunting with continuous diastolic run off

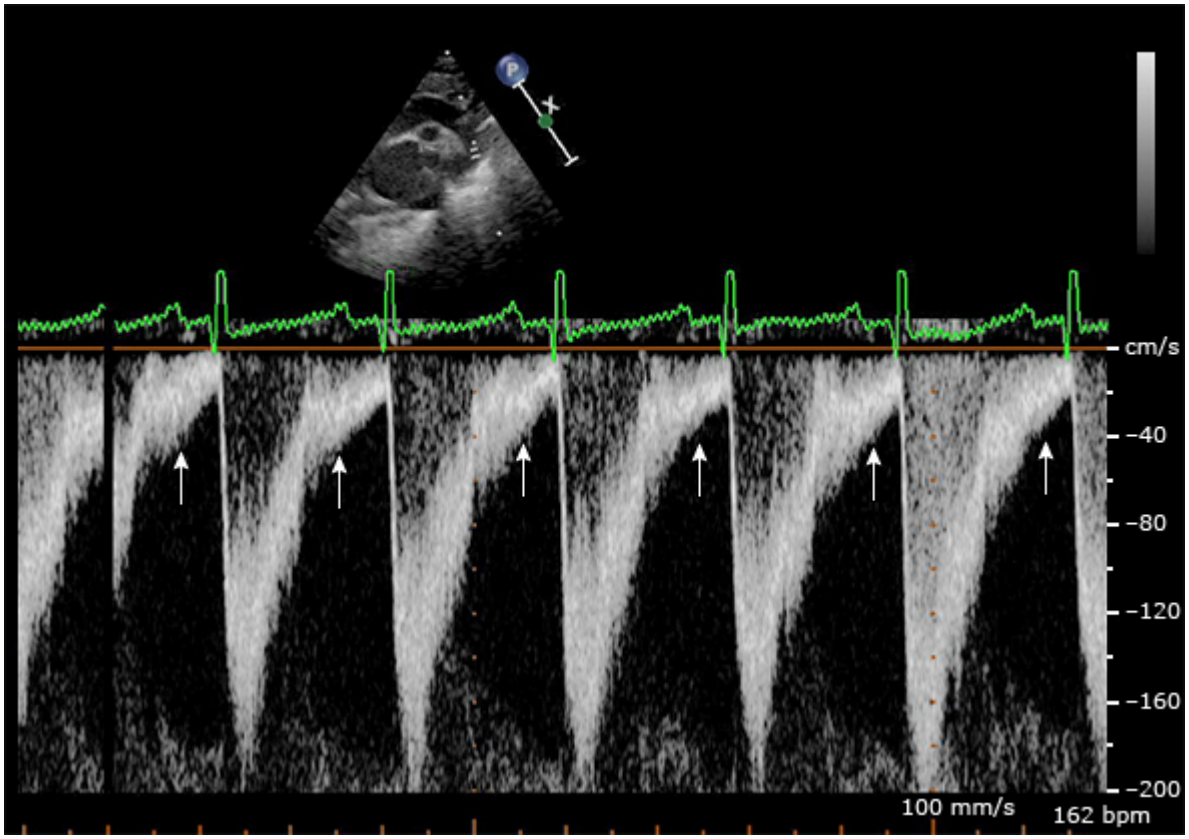

In a patient with a patent ductus arteriosus (PDA) and significant left-to-right shunting, pulsed Doppler echocardiography shows flow in the descending aorta proximal to the PDA. Note the continuous diastolic run off pattern of flow toward the ductus (arrows).

L: left; R: right.

Graphic 95164 Version 1.0

Pulsed wave Doppler interrogation in a patient with a patent ductus arteriosus and significant left-to-right shunting with retrograde diastolic flow

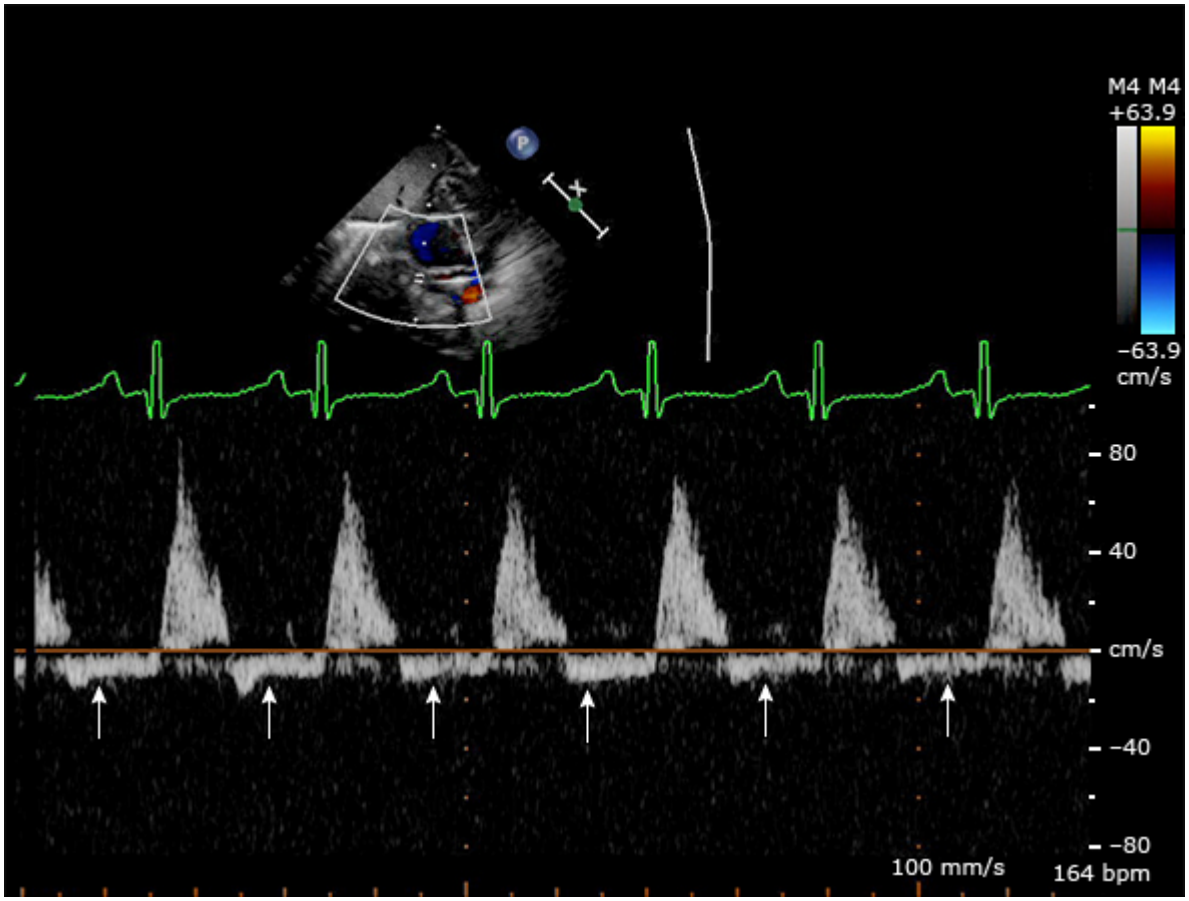

In a patient with a patent ductus arteriosus (PDA) and significant left-to-right shunting, pulsed Doppler echocardiography shows retrograde diastolic flow in the descending aorta (arrows) towards the PDA.

L: left; R: right.

Graphic 95163 Version 1.0

Pulsed wave Doppler interrogation in a patient with patent ductus arteriosus and systemic pulmonary artery pressure

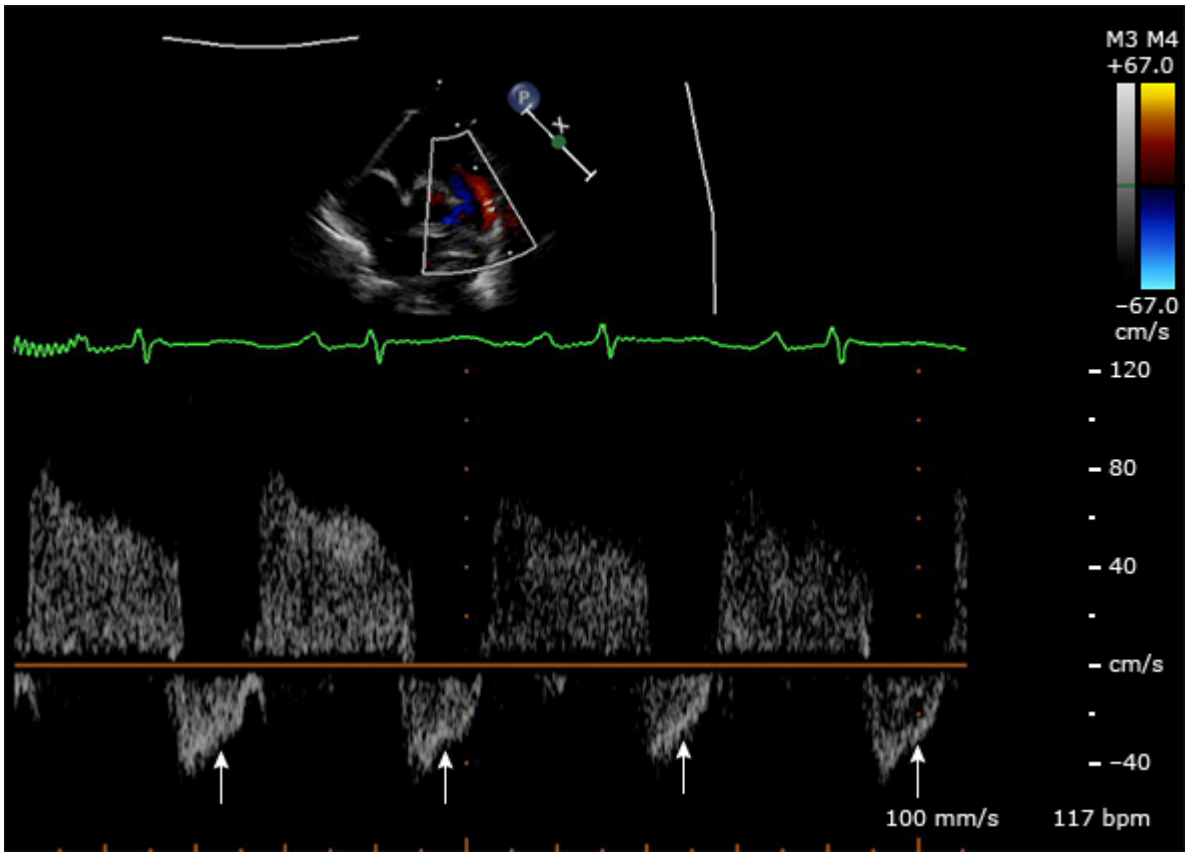

In a patient with patent ductus arteriosus (PDA) and systemic pulmonary artery pressure (PAP), pulsed Doppler echocardiography (using the short axis view) shows systolic flow (arrows) is directed away from the pulmonary artery, across the PDA, and into the descending aorta. In diastole, flow reverses and is left to right, directed toward the pulmonary artery.

Graphic 95165 Version 1.0

Contributor Disclosures

Thomas Doyle, MD Equity Ownership/Stock Options: Influent Medical, LLC [Patent ductus arteriosus]. All of the relevant financial relationships listed have been mitigated. **Ann Kavanaugh-McHugh, MD** No relevant financial relationship(s) with ineligible companies to disclose. **Heidi M Connolly, MD, FACC, FASE** No relevant financial relationship(s) with ineligible companies to disclose. **John K Triedman, MD** Consultant/Advisory Boards: Biosense Webster and Sentiar [Supraventricular and ventricular topics]. All of the relevant financial relationships listed have been mitigated. **Carrie Armsby, MD, MPH** No relevant financial relationship(s) with ineligible companies to disclose.

Contributor disclosures are reviewed for conflicts of interest by the editorial group. When found, these are addressed by vetting through a multi-level review process, and through requirements for references to be provided to support the content. Appropriately referenced content is required of all authors and must conform to UpToDate standards of evidence.

Conflict of interest policy

→